

# Biological dentistry, environmental dentistry and plasma—a combination for health

Dr Michael Rak, Arbnor Saraci, Lukas Wichnalek & Norbert Wichnalek, Germany

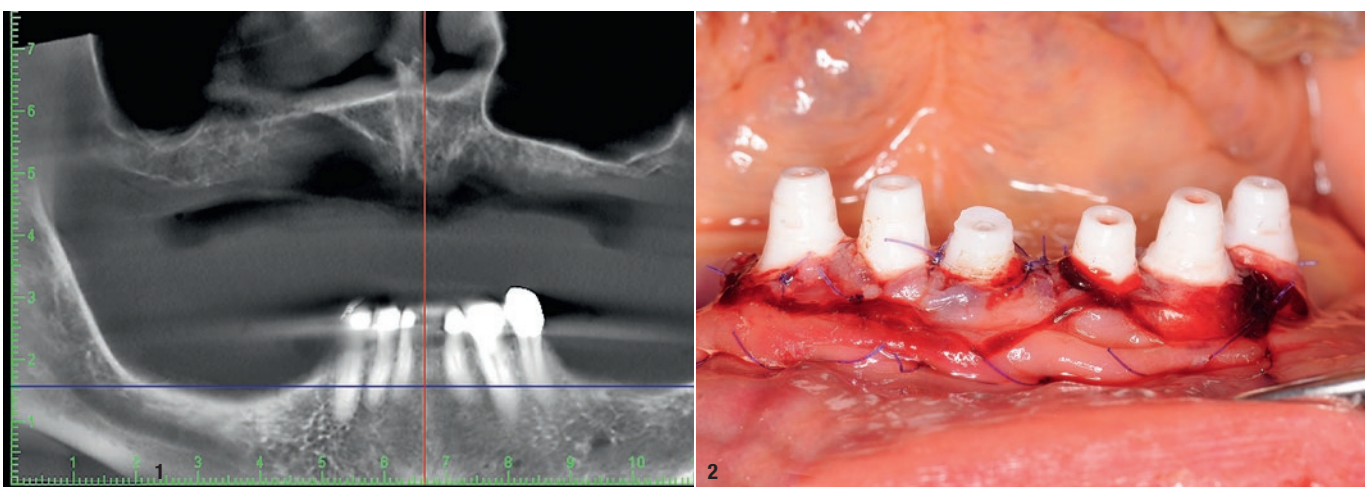
Teeth, like all other organs of the human body, have their own blood, nerve and lymph supply and are among the closest to the brain because of their localisation. A wide variety of materials, some of which are critical, are routinely inserted into this sensitive region with a view to technical longevity. The consequences can often be stressful for the entire organism. After all, the oral cavity plays a key role in prevention and recovery, as many factors that may modulate disease are associated with the oral cavity. How these challenges can be met is presented in this article by means of a case in which the health of the patient was restored with the help of ceramic implants made of zirconia and metal-free dental restorations.

Chronic cavity-forming diseases of the jaw such as fatty degenerative osteolysis of the jawbone (FDOJ), or neuralgia-inducing cavitation osteonecrosis, are still controversially discussed in oral and maxillofacial surgery today. FDOJ in the medullary cavities of the jaw bones can be identified as a lesser-known source of RANTES overexpression. The chemokine RANTES interferes with bone metabolism, leading to osteolysis in the jaw areas

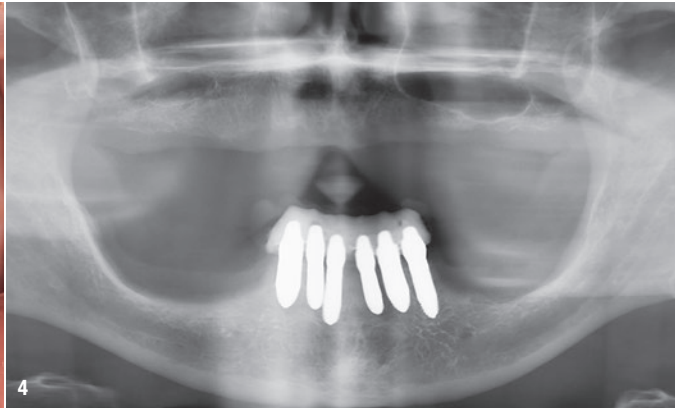
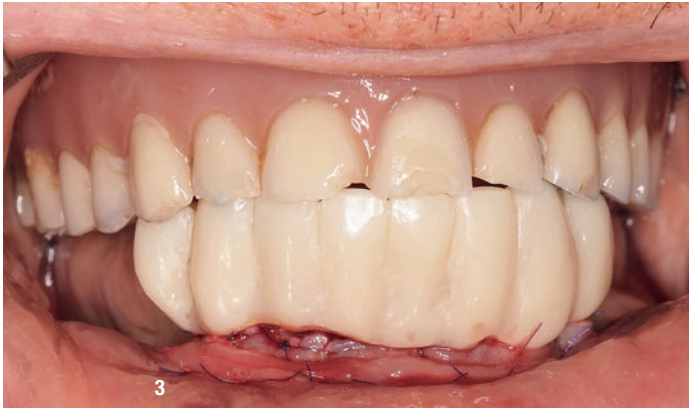affected by FDOJ. Adipocytes act pathogenetically via RANTES expression in local FDOJ and systemically on the immune system.<sup>1</sup> Biological dentistry offers healthy people adequate treatment options that have little to no effect on the organism. Even chronically ill people can be treated sustainably by means of biological dental therapy concepts that address the individual causes, gently eliminate the impairing factors and restore the original situation in a biologically compatible way without impairing the aesthetics of the teeth and the oral and maxillofacial region. For this reason, we have been combining biological dentistry with the advantages of plasma processing of all medical products (since 2017) in our dental and technical team since 2013, thus adopting a holistically oriented treatment approach.

## The fourth state of matter: Plasma

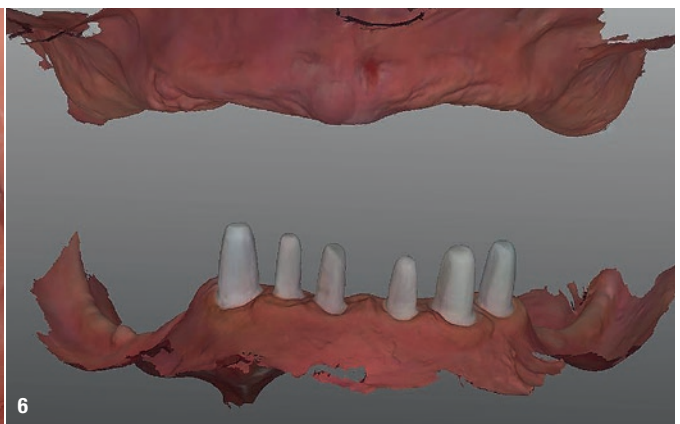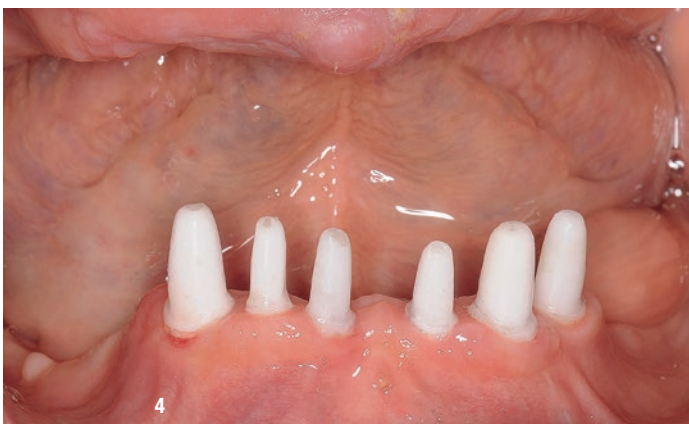Plasmas are gases such as argon or helium whose molecules are split by electricity or heated into negatively charged electrons and positively charged ions. Cold plasma generates highly reactive nitrogen or oxygen radicals and UV radiation in the ambient air. These reac-



**Fig. 1:** Dental panoramic tomogram showing six devitalised mandibular anterior teeth with partial apical osteolysis, secondary caries and horizontal bone loss in the posterior region. **Fig. 2:** The six ceramic implants placed immediately into the extraction sockets. The wounds covered with A-PRF membranes and sutured.



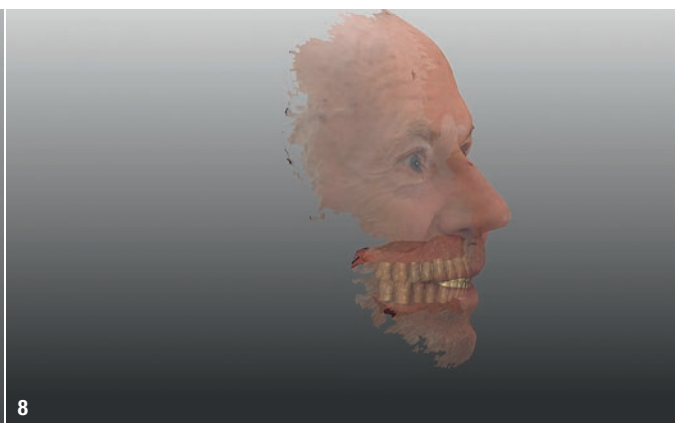
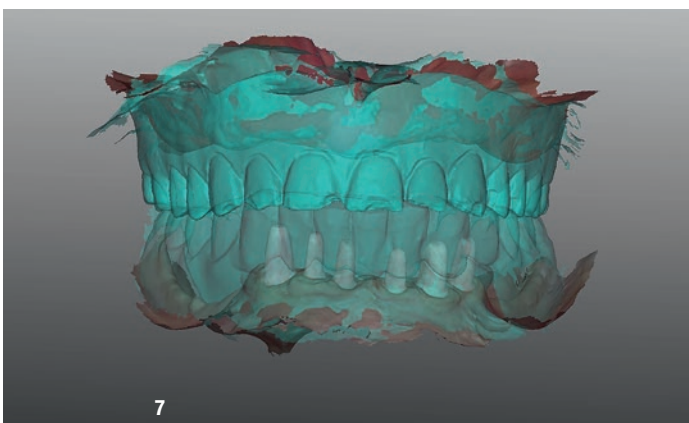
**Fig. 4:** Immediate provisional restoration placed on the implants of the same height as the old denture. **Fig. 4:** Post-op dental panoramic tomogram with the provisional restoration on the implants.



**Fig. 5:** The healed and trimmed ceramic implants in an irritation-free environment. **Fig. 6:** Intra-oral scan of the ceramic implants and the edentulous maxilla.

tive substances can penetrate bacteria and human cells because holes are torn in their membranes by the simultaneously generated electromagnetic field. In the process, bacteria die faster than cells because their genetic material is not protected by a cell nucleus. In human cells, no damage occurs with a short exposure time.<sup>2</sup> In medical applications, two plasma effects are used in particular (as of 2022):

1. inactivation of microorganisms, including multiresistant pathogens;
  2. stimulation of cell proliferation and microcirculation, resulting in the regeneration of destroyed tissue.<sup>3</sup>
- Cold atmospheric plasmas are complex mixtures of various active agents such as ozone, charged atoms, molecules and electrons, UV radiation and high electric fields. The components act synergistically on the tissue



**Fig. 7:** Matching of the intra-oral scan with the scan of the old prosthetic situation. **Fig. 8:** The digital impression from the practice integrated into the facial scan taken in the laboratory.

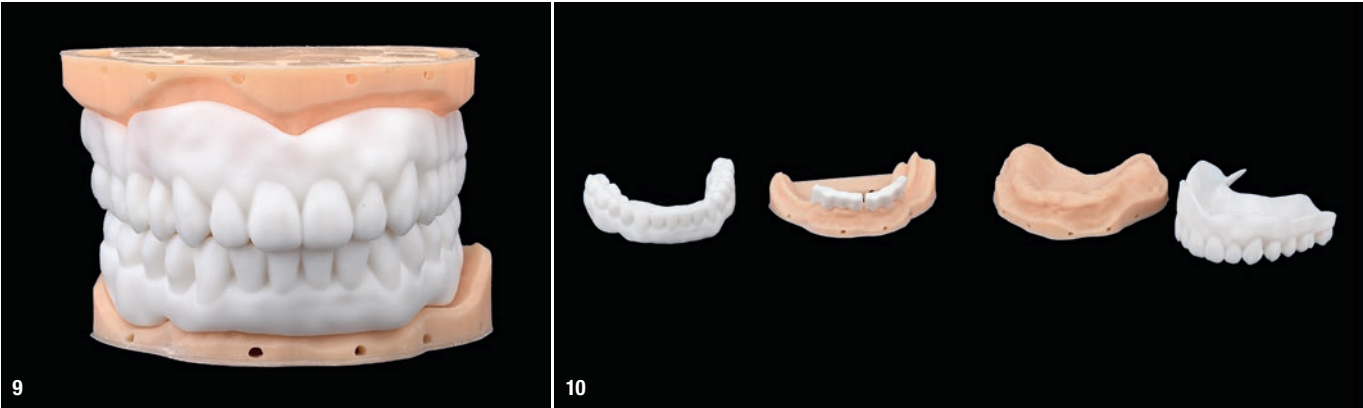


Fig. 9 & 10: The individual created trial dentures around the gingival area and the 3D-printed resin models.

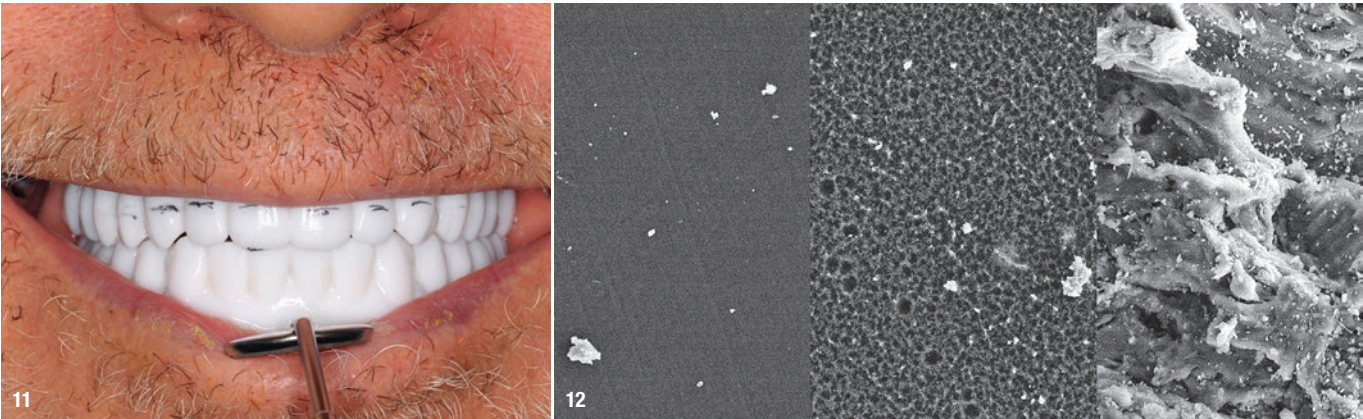


Fig. 11: Taking the bite using printed prostheses, having already considered the new bite position and aesthetics. Figs. 12: For comparison, the different surfaces. (a) Untreated. (b) Irradiated with 110 µm. (c) Surface of the PEEK framework etched with the oxygen-argon mixture.

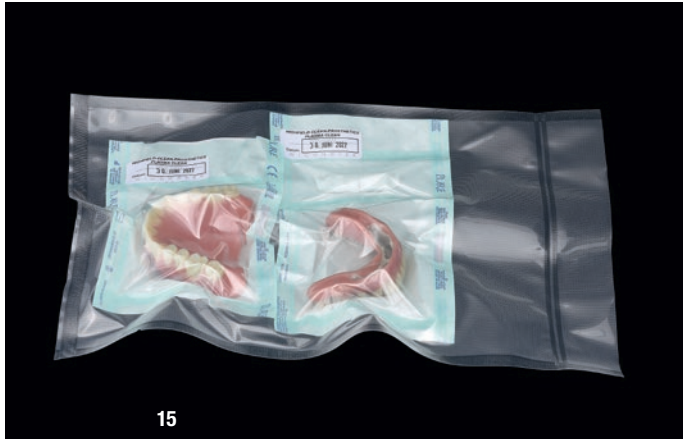
to be treated, having a range of different positive effects. The blood circulation-promoting, bacteria-reducing and skin-regenerating effects of cold plasma are relevant in the context of the wound healing process, for example in preoperative and postoperative or chronic wounds, as well as in the treatment of skin diseases.<sup>4</sup> The combination of the various active principles of plasma has a strong antibacterial and wound healing effect.<sup>5</sup>

### Use of plasma in dentistry

In dentistry, the natural gas ozone is used in a concentration compatible with health to kill bacteria and viruses.<sup>6</sup> In their 2020 study of the effects of treating nano-ZR implants with cold atmospheric plasma, Takao et al. documented another positive effect, finding that super-hydrophilicity could be achieved, although plasma treat-

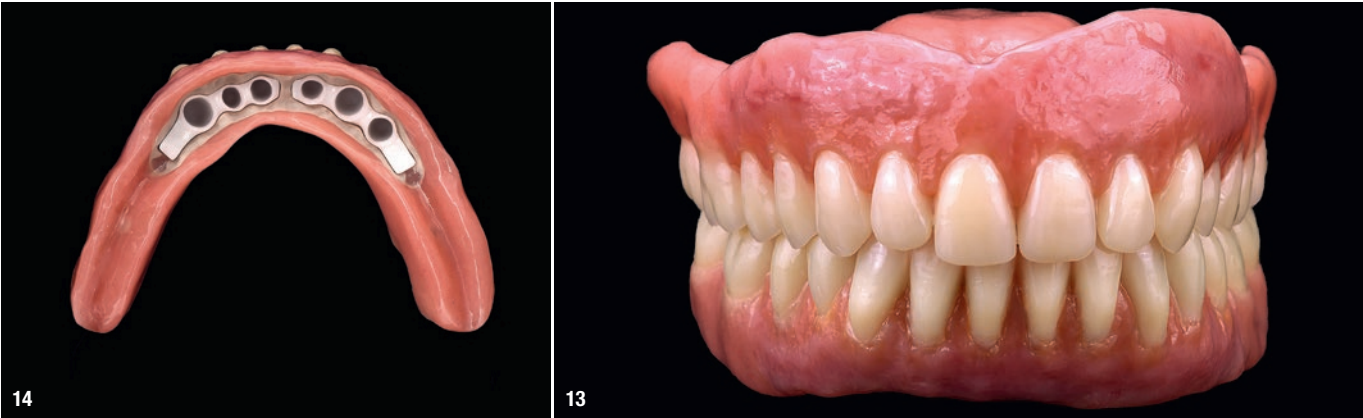

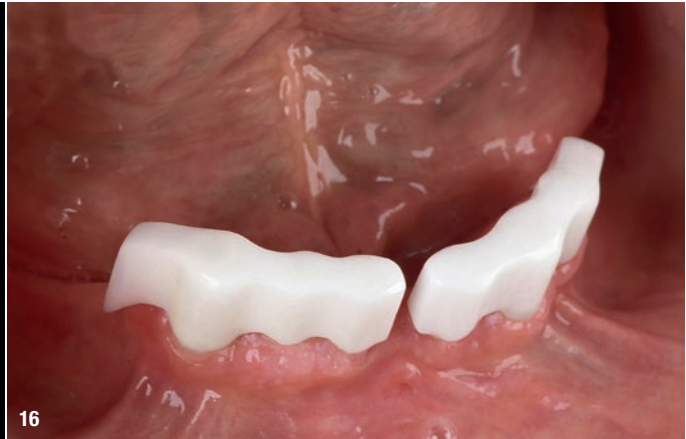Fig. 13 & 14: The finished prostheses with the integrated bars.



15



16

**Fig. 15:** Packaged prostheses after undergoing the laboratory's standard plasma cleaning. **Fig. 16:** Cemented bars in situ on three implants each.

ment does not affect the roughness of the implant.<sup>7</sup> Their *in vitro* and *in vivo* studies measured faster and better protein, cell and bone adhesion, suggesting that plasma treatment is useful as a prosthetic treatment option for patients with metal allergy.<sup>7</sup> Plasma surface activation also improves the conditions for complete osseointegration.<sup>8</sup>

### Use of plasma in the dental laboratory

Plasma enables a form-fitting and gap-free combination of high-performance plastics, such as PEEK, with other materials, for example zirconia. By activating and etching the surfaces with an ionised oxygen–argon gas mixture, the use of primers can be dispensed with in many cases. Oxygen radicals increase the surface tension, and the bombardment with argon atoms creates a micro-sandblasting effect that topographically changes the surface at the nanoscale and forms a retention base. If bonding agents are omitted, the risk for allergy patients is minimised. The ion bombardment generated in the low-pressure plasma causes the removal of organic contaminants at the nanoscale through physical and chemical processes. Bacteria and viruses are killed. The use of plasma offers an effective supplement to hygiene management in the laboratory and practice—particularly in light of the legal requirements that are becoming increasingly stricter. Abutments, superstructures, dental auxiliaries, dentures, other dental prostheses, splints and orthodontic appliances can be disinfected with low-pressure plasma. This also applies to repairs, worn dentures, acrylic dentures and implant dentures with possible fungal infestation.<sup>13</sup>

### Case presentation

The 75-year-old male patient presented to our practice with the request for a new restoration. He wore an insufficient complete denture in the upper jaw and a removable partial denture in the lower jaw on a small number

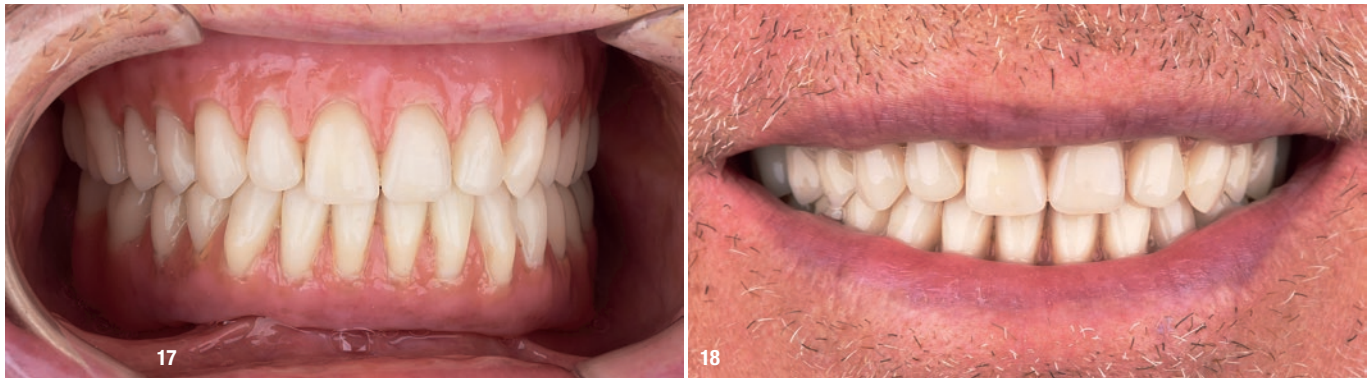of remaining teeth in the anterior. The mandibular anterior teeth were found to be devitalised and to be affected by subtle partial apical osteolysis and extensive secondary caries which affected only some of the teeth. The patient refused endodontic treatment. Instead, he expressed the wish for restoration with ceramic implants. The assessment of the patient's general condition revealed various health complaints, including frequent nocturnal urination and extensive paraesthesia and pain in his shoulders and arms. The craniomandibular dysfunction screening was within normal limits. Neural therapy with 5 ml of 1% procaine in regions #18, 17, 13, 23, 27, 28 and 43 to 34 resulted in an immediate reduction of the paraesthesia and pain symptoms. In addition to the inconspicuous apical osteolysis affecting tooth #42 and the pronounced vertical and horizontal bone loss in the posterior region, the CBCT findings revealed a bone density reduction, indicating FDOJ in regions #18, 17, 13, 23, 27 and 28 (Fig. 1).

### Therapy

Before the surgical procedures, the situation with and without the prostheses in place was recorded using an intra-oral scanner, and a digital duplicate of the prostheses was made. The first step was FDOJ restoration in regions #18, 17, 13, 23, 27 and 28, which resulted in an immediate, significant improvement in the shoulder and arm symptoms and a complete reduction in the paraesthesia. In the second step, the remaining teeth were carefully extracted, and everything was prepared for the immediate implantation of the planned six one-piece ceramic implants (SDS Swiss Dental Solutions) in the extraction sockets of regions #43 to 34. For this purpose, the implants were cleaned using plasma directly before insertion in order to achieve the highest possible bacterial reduction for the patient.

### Insertion of implants

After cleaning the extraction sockets with ozone, the six implants were inserted along with advanced plate-



**Fig. 17 & 18:** The overall situation harmoniously integrated into the mouth and face, and the optimised aesthetics in the anterior beautifully accentuated.

let-rich fibrin (A-PRF) membranes. For this purpose, the sockets were filled with A-PRF, and the implants were wet with the A-PRF exudate and inserted. The advantages of A-PRF are its high protein and platelet content. Platelets in particular contain a high amount of growth factors that accelerate bone regeneration. Various studies have shown the advantages of A-PRF wetting in extraction sockets. In guided bone regeneration or guided tissue regeneration, the A-PRF membrane provides improved dimensional stability of the bone compared with the natural healing process. It has been shown that filling the extraction sockets with PRF reduces the risk of osteomyelitis almost tenfold. Thus, the PRF membrane ensures improved and accelerated bone regeneration and healing, as well as maintains the quality and density of the residual alveolar ridge. The risk of infection is also significantly reduced.<sup>9-12</sup> This method of preparation created the best conditions for the healing of the inserted implants without complications. Finally, the wounds were closed with resorbable suture (Fig. 2). For the healing phase, a chairside-fabricated provisional restoration was placed on the implants with a discreet attachment in region #44 and a pontic in region #31, achieving an even occlusion and the best possible aesthetics (Fig. 3). The provisional res-

toration was of the same height as the removable mandibular denture. Finally, the correct fit of the implants with the provisional restoration in place was checked radiographically, and the patient was discharged (Fig. 4).

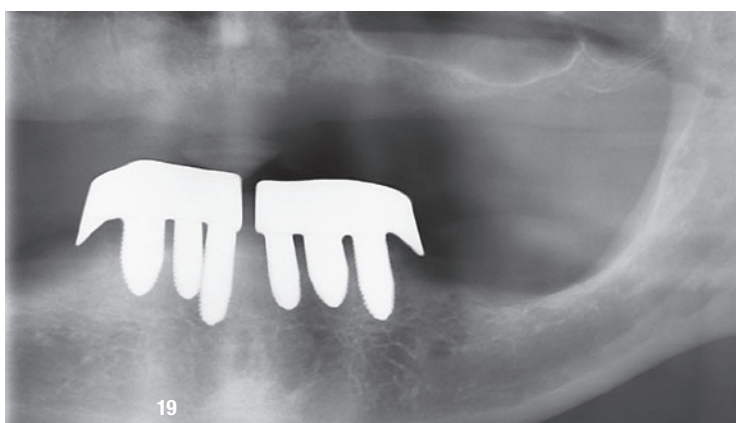
We checked the situation again about 14 weeks later. After removal of the provisional restoration, the gingiva was free of irritation and the implants were osseointegrated (Fig. 5). The Periotest (Medizintechnik Gulden) and the insertion test to between 15 and 20 N cm did not cause any rotation or pain. We then scanned the implants with an intra-oral scanner, matched the new situation with the scan of the initial situation and sent the patient to the laboratory (Figs. 6 & 7).

#### Facial scan and fabrication of the dentures

A telescopic mandibular prosthesis made of PEEK on zirconia bars and a complete maxillary denture made of PMMA were planned. First, a facial scan was taken in the laboratory, and the digital impression from the practice was integrated into it (Fig. 8). Based on this data, the facial analysis and the correct positioning of the dentition were carried out. Based on the results, the mandibular bars were designed using backward planning and milled from the ultra-hard zirconia VITA YZ TWhite (VITA Zahnfabrik). The gingival area was then added to the individual set-up, and the trial dentures and resin models were 3D-printed (Figs. 9 & 10). These were used by the practice for bite checking and bite taking (Fig. 11). The unfavourable aesthetics in the anterior were digitally optimised, and the anterior teeth in the upper jaw were lengthened. After minimal corrections of the occlusion, the bite was encoded, and the trial dentures were sent back to the laboratory. A functional impression was taken of the bar frameworks.

At the next appointment, we were already able to check the wax-up of the maxillary and mandibular dentures. The occlusion was checked again, fine-tuned and coded again by means of bite registration.

In order to prepare the smooth surfaces of the PEEK framework for secure bonding to the ready-made teeth,



**Fig. 19:** Confirmation radiograph after insertion of the complete denture in the lower jaw.

everything was exposed to an oxygen–argon mixture in the vacuum chamber of the DENTAPLAS plasma unit (Diener electronic) according to a specially stored and reproducible program. The result was an etched, wonderfully retentive surface (Fig. 12). In the finished telescopic prosthesis, the receptacles for the friction parts with the integrated bars were sealed with composite (Figs. 13 & 14). If necessary, these could be easily reopened and supplemented with the zirconia resin friction parts. Finally, the prostheses were disinfected via plasma and packaged according to the laboratory's standard plasma cleaning concept and handed over to the practice for insertion (Fig. 15).

### Insertion in the practice

As soon as the final prostheses arrived in the practice from the laboratory, the bars were placed on the implants and firmly cemented in place (Fig. 16). The prostheses were then inserted, and the fit was visually checked once again. It was satisfying to see how harmoniously the overall situation integrated into the mouth and face. The optimised aesthetics of the anterior also turned out beautifully (Figs. 17 & 18). Finally, the situation was checked with the help of a radiograph (Fig. 19).

### Conclusion

In 2013, Canullo et al. compared the clinical results of two different procedures of preparing abutments before they were placed in patients. In one group, the abutments were treated with hot steam, and in the other group by means of an argon plasma reactor. After two years, significantly higher peri-implant bone resorption was found in the group with abutments treated with hot steam compared with the group with abutments treated with plasma.<sup>14</sup> In a statement by the German working group for hygiene in dentistry (Deutscher Arbeitskreis für Hygiene in der Zahnmedizin), the question was raised of whether the results of the study by Canullo et al. were due not to different microbial contamination but to surface changes of the abutments as a result of the plasma treatment, which had led to more stable peri-implant tissue attachment.<sup>15</sup> It is known that treatment of implants with certain plasmas, in addition to cleaning and disinfection, can lead to surface modification, the effect of which is better interaction with the surrounding tissue (bone or soft tissue) and ultimately better osseointegration of the implants. Such an effect has also been discussed in various publications regarding implants treated with argon plasma. It can be assumed that such a change in the surface of the abutments also took place through the argon plasma treatment used by Canullo et al., influencing wound healing.<sup>16</sup> Based on Canullo et al.'s positive results, we decided in the team not only to completely dispense with any metals, but also to thoroughly clean and disinfect with plasma all medical devices that are incorporated into the body.

## contact

**Dr Michael Rak**  
info@praxis-dr-rak.de  
www.praxis-dr-rak.de



**Arbnor Saraci**



**Lukas Wichnalek**



**Norbert Wichnalek**  
info@wichnalek-dl.de  
www.wichnalek-dl.de

